



**Radiology Techniques Department**  
**Special Radiological Procedures-1**

**lecture 5**

***Barium Follow Through***

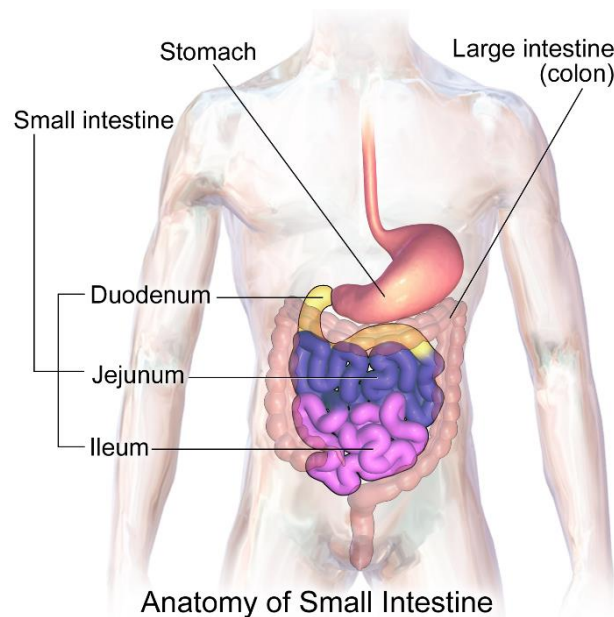
**By**

**MR.T Hussein Ayyed**  
**MS.c Nariman Neamah**

## Barium Follow Through

This test is similar to a barium meal but aims to look for problems in **the small intestine**.

**Small Intestine:** The upper part of the intestine, between the stomach and the large intestine, that is divided into the **duodenum**, the **jejunum**, and the **ileum**.



### Methods

1. Single contrast
2. With the addition of an effervescent agent
3. With the addition of a pneumocolon technique

### Contraindications

1. Complete or high-grade obstruction is better evaluated by CT examination.
2. Suspected perforation is better evaluated by CT.

## Indications

1. gastrointestinal bleeding (GI bleeding)
2. Partial obstruction
3. Malabsorption, or diarrhea or pain with weight loss
4. diverticula
5. Small bowel adhesive obstruction (water soluble contrast)

## Contrast Medium

Barium E-Z Paque 100% w/v.

**In adult 300 mL** (or as required) usually given divided over **20 min.**

**In children, 3–4 mL kg<sup>-1</sup>** is a suitable volume.

**The transit time** through the small bowel is **reduced by the addition** of **10 mL** of water-soluble contrast agents (frequently **Gastrografin**) to the barium. (if patient with small bowel adhesive obstruction use water-soluble contrast agents as Gastrografin or LOCM)

## Patient Preparation

1. Patient fasting at midnight.
2. Maxolon 20 mg orally may be given before or during the examination to enhance gastric emptying.

## Preliminary Image

If vomiting, a plain abdominal film should be performed to exclude high-grade small bowel obstruction.

## Technique

The aim is to deliver a **single continuous column of barium** into the small bowel. This is achieved by the addition of **10 mL of Gastrografin** to the barium solution and the patient **lying** on their **right** to **enhance gastric emptying**.

If a follow-through examination is combined with a barium meal, **glucagon** can be used for the duodenal cap views **rather than Buscopan**, **because** it has a short length of action and does not interfere with the small-bowel transit time. **Normal small bowel transit** ranges between **30-120 minutes**

## Images

1. **Prone PA** images of the abdomen are taken every **15–20 min** during **the first hour**, and **subsequently every 20–30 min until reached to the colon**. The **prone position** is used because the pressure on the abdomen **helps separate the loops of the small bowel**.
2. Each image should be reviewed and spot supine fluoroscopic views, using a compression device or pad if appropriate, may be considered.
3. Dedicated spot views of the terminal ileum are routinely acquired.

## Additional Images

1. To separate loops of the small bowel:
  - (a) compression with fluoroscopy
  - (b) with x-ray tube angled into the pelvis

(c) **obliques**—in particular with the **right side raised** for **views of the terminal ileum**

(d) **pneumocolon**—gaseous insufflation of the colon via a rectal tube after barium arrives in the caecum, which often results in good-quality double-contrast **views of the terminal ileum**

2. **Erect image**—Occasionally used to reveal any fluid levels caused by contrast medium **retained within diverticula**.

### **Aftercare (As for barium meal)**

1. Patient warned about white stool
2. Patient not leave before blurring by buscopan is revealed
3. Eat and drink as normal but with extra fluids

### **Complications (As for barium meal)**

1. Leakage of barium from an unsuspected perforation
2. Aspiration
3. Conversion of a partial large bowel obstruction into a complete obstruction by the impaction of barium
4. Barium appendicitis (very rare)
5. Side effects of the pharmacological agents used